


This article was downloaded by: [Wake Forest University]

On: 04 January 2015, At: 20:40

Publisher: Routledge

Informa Ltd Registered in England and Wales Registered Number: 1072954 Registered office: Mortimer House, 37-41 Mortimer Street, London W1T 3JH, UK



Journal of Neurotherapy: Investigations in Neuromodulation, Neurofeedback and Applied Neuroscience

Publication details, including instructions for authors and subscription information:

<http://www.tandfonline.com/loi/wneu20>

Connectivity Theory of Autism: Use of Connectivity Measures in Assessing and Treating Autistic Disorders

Robert Coben PhD^a & Thomas E. Myers MS^a

^a Neurorehabilitation & Neuropsychological Services, Massapequa Park, New York

Published online: 12 Dec 2008.

To cite this article: Robert Coben PhD & Thomas E. Myers MS (2008) Connectivity Theory of Autism: Use of Connectivity Measures in Assessing and Treating Autistic Disorders, *Journal of Neurotherapy: Investigations in Neuromodulation, Neurofeedback and Applied Neuroscience*, 12:2-3, 161-179, DOI: [10.1080/10874200802398824](https://doi.org/10.1080/10874200802398824)

To link to this article: <http://dx.doi.org/10.1080/10874200802398824>

PLEASE SCROLL DOWN FOR ARTICLE

Taylor & Francis makes every effort to ensure the accuracy of all the information (the "Content") contained in the publications on our platform. However, Taylor & Francis, our agents, and our licensors make no representations or warranties whatsoever as to the accuracy, completeness, or suitability for any purpose of the Content. Any opinions and views expressed in this publication are the opinions and views of the authors, and are not the views of or endorsed by Taylor & Francis. The accuracy of the Content should not be relied upon and should be independently verified with primary sources of information. Taylor and Francis shall not be liable for any losses, actions, claims, proceedings, demands, costs, expenses, damages, and other liabilities whatsoever or howsoever caused arising directly or indirectly in connection with, in relation to or arising out of the use of the Content.

This article may be used for research, teaching, and private study purposes. Any substantial or systematic reproduction, redistribution, reselling, loan, sub-licensing, systematic supply, or distribution in any form to anyone is expressly forbidden. Terms & Conditions of access and use can be found at <http://www.tandfonline.com/page/terms-and-conditions>

Connectivity Theory of Autism: Use of Connectivity Measures in Assessing and Treating Autistic Disorders

Robert Coben, PhD
Thomas E. Myers, MS

ABSTRACT. *Background.* Autism is a disorder characterized by deficits in communication, social interaction, a limited range of interests, and repetitive stereotypical behavior. Although it is believed that changes in the brain leading to Autism occur early on in prenatal and early postnatal development, there is no definitive test for a diagnosis of Autism. The diagnosis is made on the basis of behavioral signs and symptoms alone and is usually not made until age 2 or later. There have been numerous neuroanatomical abnormalities noted in Autism, some of which can be linked to neuropsychological dysfunction. Recently a new theory has become prominent which suggests the disorder may be due to aberrant neural connectivity patterns. Evidence in support of this theory has come from anatomical studies of white matter as well as functional neuroimaging studies.

Methods. Most studies have employed functional magnetic resonance imaging to investigate connectivity, or electroencephalography (EEG) coherence studies. The high temporal resolution of EEG lends itself well to the investigation of cerebral connectivity. Research suggests there may be patterns of both hyper- and hypoconnectivity between various brain regions. Seven different patterns of abnormal connectivity which can be analyzed with EEG are proposed.

Results. Patterns of hyperconnectivity may be found in frontotemporal and left hemispheric regions, whereas patterns of hypoconnectivity are often seen in frontal (orbitofrontal), right posterior (occipital/parietal-temporal), frontal-posterior, and left hemispheric regions. In addition to these patterns of hypo- and hyperconnectivity, a mu rhythm complex has been identified. Treatment goals may be based on coherence anomalies identified by quantitative EEG analysis. Increased coherence between brain regions may be downtrained, whereas decreased coherence between brain regions may be uptrained. Clinical examples of each pattern and a discussion of their neurofeedback treatment are provided.

Conclusion. A theory of autistic disorders is presented that has at its' core neural connectivity disturbances. Multivariate EEG connectivity indices are utilized to formulate a typology of connectivity anomalies or patterns that have been observed over a series of autistic patients.

Robert Coben is Director, Neurorehabilitation & Neuropsychological Services, Massapequa Park, New York.

Thomas E. Myers is affiliated with Neurorehabilitation & Neuropsychological Services, Massapequa Park, New York.

Address correspondence to: Robert Coben, PhD, Director, Neurorehabilitation & Neuropsychological Services, 1035 Park Boulevard, Suite 2B, Massapequa Park, NY 11762 (E-mail: robcoben@optonline.net).

These represent phenotypic expressions of the underlying pathology that leads to autistic symptoms. Examples demonstrate how these connectivity metrics can be used to understand autistic disturbances and formulate neurofeedback strategies for remedying these difficulties.

KEYWORDS. Assessment, autism, coherence, EEG, hypo/hyperconnectivity, neurofeedback, theory, treatment

Autistic spectrum disorders (ASDs) are a group of pervasive developmental disabilities characterized by deficits in communication, social interaction, and restricted repetitive behavior. The spectrum includes Autistic Disorder, Rett's Disorder, Childhood Disintegrative Disorder, Asperger Disorder, and Pervasive Developmental Disorder Not Otherwise Specified (PDD-NOS; Tidmarsh & Volkmar, 2003). Research indicates the prevalence of these disorders is on the rise, with studies indicating that about 1 out of 150 eight-year-old children will be diagnosed with an ASD (Centers for Disease Control and Prevention, 2006). Although persons with ASD share some similarity, each disorder has its own unique characteristics, which permit different diagnoses. Autistic Disorder is characterized by impaired social interaction, delay, or total lack of spoken language and communication, as well as repetitive stereotyped behaviors, interests or activities (American Psychiatric Association, 2000). Asperger's Disorder is often associated with high cognitive function, literal pedantic speech, difficulty comprehending implied meaning, problems with fluid movement, and inappropriate social interaction. PDD-NOS refers to the category of deficits in language and social skills that do not meet the criteria for other disorders. In contrast, Childhood Disintegrative Disorder and Rett's Disorder are characterized by intervals of normal early development followed by loss of previously acquired skills. Although communication and social skill deficits are common among these conditions, there remains a substantial degree of variability in terms of onset and severity of symptomatology within the autistic spectrum of disorders (Attwood,

1998; Hamilton, 2000; McCandless, 2005; Sicile-Kira, 2004; Siegel, 1996).

NEUROPATHOLOGY IN AUTISM

Early evidence of abnormal brain morphology came from Kanner (1943), who noted an enlargement of the heads of autistic children. Kanner's anecdotal findings were then corroborated by a plethora of more controlled studies. Macrocephaly has been found in approximately 20% of autistic individuals (Bailey, Luthert, & Bolton, 1993; Courchesne, Carper, & Akshoomoff, 2003; Davidovich, Patterson, & Gartside, 1996) and is supported by results from neuroimaging (Courchesne et al., 2001; Filipek et al., 1992; Piven, Arndt, Bailey, & Andreasen, 1996) and increased brain weight (Bailey et al., 1998; Courchesne, Muller, & Saitoh, 1999). Specifically, there may be an increase in temporal, parietal, and occipital lobe volume but not the frontal lobe (Piven et al., 1996). This pattern may be interpreted as either abnormal posterior brain enlargement or a frontal lobe abnormality in which the frontal lobes lag behind the rest of the brain in their development.

Kemper and Bauman (1993) investigated alterations in limbic areas by reviewing the findings of several case reports. Their analyses from six autistic subjects of varying ages revealed increased cell packing density and reduced cell size in the hippocampus, subiculum, amygdala, and to a lesser extent in the entorhinal cortex, mammillary bodies, and septal nuclei. Other studies showed a decrease in Purkinje cell density in the cerebellum of autistic cases (Bailey et al., 1998; Kemper & Bauman, 1993). Kemper

and Bauman (1998) interpreted these findings as a hindrance in the normal developmental process, probably largely prenatal in origin. Other brain abnormalities include cortical dysgenesis, as evidenced by increased neuronal density, thickened cortex, presence of neurons in the molecular layer, irregular laminar patterns, and poor gray-white matter boundaries (Bailey et al., 1998), suggesting aberration in cortical lamination and apoptosis (Rorke, 1994).

In an attempt to localize cerebral dysfunction in Autism, various functional neuroimaging studies were conducted. Schmitz et al. (2006) utilized functional magnetic resonance imaging (fMRI) to examine the neural correlates of executive function in ASD. Their findings indicated that ASD individuals had significantly increased brain activity, as indicated by the blood oxygen level dependent (BOLD) response, associated with the left inferior and orbital frontal gyrus (associated with motor inhibition), left insula (regulating interference inhibition), and parietal lobes (required for set shifting). Increased frontal gray matter density in areas of increased functional activation was also observed in ASD (Schmitz et al., 2006). In a proton magnetic resonance spectroscopy study, increased frontal metabolite levels were associated with obsessive behavior in Asperger Syndrome (Murphy et al., 2002). Anomalies in brain metabolites were reported in amygdala-hippocampal regions in ASD (Page et al., 2006). Using positron emission tomography (PET), Boddaert et al. (2002) found significant bilateral temporal hypoperfusion in the superior temporal gyrus and superior temporal sulcus in 77% of the children with Autism. Other research utilizing functional neuroimaging linked social cognition dysfunction and language deficits in Autism to neural substrates (Just, Cherkassky, Keller, & Minshew, 2004; McAlonan et al., 2005; Pelphrey, Adolphs, & Morris, 2005; Welchew et al., 2005).

McAlonan et al. (2005) investigated brain structural changes linked to Autism using voxel-based MRI. Their results indicated that children with Autism had a significant reduction in total gray matter volume, particularly within fronto-striatal and parietal networks

and increased cerebral spinal fluid volume. In addition, white matter was reduced in the cerebellum, left internal capsule, and fornices (McAlonan et al., 2004). Herbert et al. (2003) performed an MRI-based morphometric analysis of the brains of 17 autistic children to investigate both total brain volume and specific brain regions and found whole brain volume was moderately increased. Factor analysis was then used to subgroup brain regions based on intercorrelations. The first grouping showed enlargement of diencephalon, caudate, globus pallidus-putamen, cerebellum and brainstem areas. Their second grouping suggested possible smaller adjusted volumes in the autistic group in cerebral cortex and hippocampus-amygdala. The third grouping, which included cerebral white matter, showed increased volume compared to controls.

The study by Herbert et al. (2003) demonstrated the heterogeneity of brain differences in autism and the difficulty in looking for a specific brain area to be implicated in the disorder. It was suggested that there may be abnormalities in the pathways and that pervasive core processing deficits, impaired complex information processing, or weak central coherence in Autism may be associated with abnormal white matter. Deficits in cross-modal information processing and intrahemispheric as well as corticocortical connections may be linked to behavior and communication impairment in Autism (Herbert et al., 2004). Cell minicolumn anomalies of the cerebral cortex representing connectivity linking afferent, efferent, and interneuronal connections have been reported in Autism (Casanova, Buxhoeveden, & Brown, 2002). Abnormal neural connectivity can affect different levels of processing within local networks (Bertone, Mottron, Jelenic, & Faubert, 2005). Research utilizing two-dimensional voxel-based morphometry to identify white matter density as an index of neural connectivity indicated that Autism is associated with reduced white matter concentration (Chung, Dalton, Alexander, & Davidson, 2004). Piven, Bailey, Ranson, & Arndt (1997) examined regions of the corpus callosum in autistic individuals, finding decreased size in the

body and posterior regions but not anterior subregions of the corpus callosum.

NEURAL CONNECTIVITY DEFICITS IN AUTISM

The aforementioned research and multiple brain regions implicated in Autism provide support for neural connectivity deficits in Autism. Frith (2003) suggested that autistic behaviors may be explained by their lack of ability to integrate information and instead to focus obsessively on details. She believed that this was because of a lack of communication between frontal brain areas that would typically integrate the information with more posterior areas (Wickelgren, 2005). Since that time, much research has been conducted in support of this connectivity deficit hypothesis.

Research utilizing fMRI has reported a pattern of underconnectivity in Autism (Just, Cherkassky, Keller, Kana, & Minshew, 2007). A decreased degree of synchronization (the correlation of time series activation) between frontal and parietal areas of activation was noted during a task of executive function. Furthermore, the size of the genu of the corpus callosum was correlated with frontal-parietal connectivity. These findings suggest that cortical underconnectivity is associated with a deficit in the neural and cognitive integration of information (Just, Cherkassky, Keller, Kana, & Minshew, 2007). McAlonan et al. (2005) found anomalies in the anatomy (reduction in total gray matter volume) and connectivity (associated with interregional gray matter correlations) of limbic-striatal social brain systems in Autism. Just, Cherkassky, Keller, & Minshew (2004) found evidence of underconnectivity associated with reduced cortical activation and synchronization as indicated by number of voxels activated during an fMRI sentence comprehension task.

In addition to disturbed connectivity during cognitive tasks, functional underconnectivity was reported in the resting brain state in Autism (Cherkassky, Kana, Keller, & Just, 2006). By comparing the resting-state in an autistic group to a control group using fMRI, the two groups showed similar levels of activation. However, the autistic group showed lower

functional connectivity between various brain regions. Specifically, they found significantly decreased connectivity between the anterior cingulate region with the posterior cingulate and precuneus, between the left parahippocampal gyrus with various other regions, and lower overall left hemisphere connectivity. In addition, they found a positive correlation between the size of the rostral body of the corpus callosum and functional connectivity between the left frontal and posterior regions in Autism. The lack of coordination among neural centers in Autism is evident in the resting state as well as during complex tasks and provides support for Autism as a disorder of neural systems rather than a focal disorder (Cherkassky et al., 2006).

Autism has also been classified as a disorder of arousal-modulating systems associated with atypically increased functional connectivity in addition to areas of underconnectivity. Research utilizing fMRI BOLD signal during simple visuomotor coordination has indicated greater thalamocortical functional connectivity in Autism. Excessive connectivity was noted in the left insula, right postcentral, and middle frontal regions. Increased thalamocortical functional connectivity may be associated with excessive synaptic generation and reduced pruning, which may be linked to brain enlargement in Autism (Mizuno, Villalobos, Davies, Dahl, & Muller, 2006).

Courchesne and Pierce (2005) described a pattern of overconnectivity (hyperconnectivity) within the frontal lobe, with long-distance disconnection (hypoconnectivity) between the frontal lobe and other brain regions associated with ASD. This pattern of abnormal connectivity disrupts the ability of the frontal lobes to integrate information from emotional, language, sensory, and autonomic systems (Courchesne & Pierce, 2005). Because EEG measures electrical activity across the brain with high temporal resolution, it lends itself well to the investigation of connectivity through EEG coherence measurement.

EEG FINDINGS IN AUTISM

Computerized EEG analyses indicated that children with Autism have significantly

greater coherence between hemispheres in the beta band than mentally handicapped, normal children, or toddlers (Cantor, Thatcher, Hrybyk, & Kaye, 1986). They also had higher coherence in the alpha band than normal controls and less inter- and intrahemispheric asymmetry than either normal controls or mentally handicapped children. These findings would appear to suggest that the EEG is a useful and valid means of measuring connectivity anomalies in this population.

Murias, Webb, Greenson, and Dawson (2007) assessed functional connectivity with EEG coherence during an eyes closed resting state. Relative to controls, individuals with ASD showed long range alpha band coherence reductions in frontal-occipital and frontal-parietal areas. The alpha band represents more globally dominant functions, which are more dependent on cortico-cortical and callosal fibers (Nunez, 1995; Nunez & Srinivasan, 2006). Individuals with ASD also showed increased coherence at temporal recording sites between 3 and 6 Hz, reflecting intact locally dominant cortical activity. These findings support the hypothesis of a weak connection between frontal and other areas.

Coben, Clarke, Hudspeth, and Barry (2008) using quantitative EEG (QEEG) found that autistic children showed decreased intrahemispheric coherences across short-medium as well as long interelectrode distances within delta and theta bands. In addition, there were reduced interhemispheric coherences in the alpha band in temporal regions, and reduced interhemispheric coherences in beta in central, parietal, and occipital regions. Greater relative theta was especially prevalent in the right posterior region, while lower beta was noted across the right hemisphere, especially over the right frontal region.

CONNECTIVITY THEORY

The most robust white matter fiber tract in the brain, the corpus callosum, connects

most of the two cerebral hemispheres and plays a major role in cerebral connectivity. Several studies have found this pathway to be aberrant in Autism. Courchesne, Press, and Yeung-Courchesne (1993) found thinning, particularly in the posterior body of the corpus callosum. Since their original finding, several others have found abnormalities of the corpus callosum including decreased density in the genu, and splenium (Chung et al., 2004; Vidal et al., 2006), disproportionately smaller corpus callosum relative to cerebral volume (Boger-Megiddo et al., 2006), and small corpus callosum volumes, high mean diffusivity, low anisotropy, and increased radial diffusivity (Alexander et al., 2007).

Although numerous studies suggest there is an increase in total brain volume in Autism, this anomaly does not appear to be present at birth. Rather, during the first 2 years of life there is overgrowth, followed by a decrease in the normal growth process (Courchesne, 2004; Courchesne et al., 2001). It was suggested that the reason for this abnormal growth process is that there may be dysfunction in the normal pruning process (Frith, 2003). By dividing cerebral white matter with a white matter parcellation technique, Herbert et al. (2004) found that the increase in white matter was in the radiate (outer) zones of all cerebral lobes and longer myelinating regions. In contrast, inner zone white matter volumes showed no difference compared to a control group. Because deeper myelination occurs earlier on, the authors interpreted this finding as supporting a postnatal disturbance which disrupts primarily intrahemispheric and cortico-cortical connections.

In a review of neuropathological findings in Autism, Herbert (2005) indicated that neuroinflammation is present in Autism and contributes to the increased cranial volume. The overall increase in volume may result in dysfunction of the ability to integrate information between different parts of the brain. Herbert further speculated that disconnectivity may result in specific dysfunction, not just pervasive, nonspecific deficits. Therefore, domains

most likely to be affected by the inflammatory response are those which require more coordination and communication between brain areas, such as language and executive functioning.

Courchesne, Redcay, Morgan, and Kennedy (2005) provide a detailed explanation of the disruption of connectivity in the autistic brain. There are an excess number of neurons in the frontal cortex but not in lower/basic level systems. Excess frontal cortical neurons may produce excessive connectivity, as neurons that are excited near one another will tend to connect to each other. Nonfrontal cortical connectivity, on the other hand, would be diminished because of a lack of coherent bursts of activity. The result is a hyperconnected frontal cortex “disconnected” from the rest of the brain (Courchesne & Pierce, 2005). This local hyperconnectivity within frontal cortex is disorganized, however, preventing normal frontal lobe functioning. Normally, frontal cortex is responsible for integrating and directing different brain areas. Clearly, this ability is critically dependent on intact connections with other brain regions, and is shown to be severely disrupted in autism.

The connectivity theory of autism has become an empirically supported theory describing the neurobiological basis of Autism, with evidence suggesting that it is an overgrowth of white matter during the first 2 years of life, followed by a retardation of growth thereafter, which leads to disordered connectivity (Hughes, 2007). At least two critical issues result from the aforementioned findings. First, through scientific investigation, we must learn how to prevent these problems from taking place. Second, we must improve the evaluation and treatment of connectivity disturbances after they occur. The EEG appears to be good candidate for the evaluation of neural connectivity in Autism, based on coherence analyses. Specifically, we propose that EEG neurofeedback can be utilized to remedy aberrant coherence patterns. Next we discuss connectivity evaluations and how neurofeedback has been used to treat them.

CONNECTIVITY PATTERNS IN AUTISM

Evidence from the research studies just discussed and data from recent EEG coherence studies indicate that there may be as many as seven abnormal connectivity patterns in Autism. These connectivity patterns were determined based on research studies we have conducted as well as clinical observation and experience. QEEG analysis measures functional connectivity between different areas of the brain based on phase synchrony, or the degree to which two signals maintain a phase locked relationship over time (Walker, Norman, & Weber, 2002). Another, more pure view of coherence is defined by Otnes and Enochson (1972) as the squared cross-correlation between two waveforms within a given frequency band that has been normalized for amplitude. Consistent with existing research showing disordered connectivity, coherence anomalies appear to be the primary dysfunction in Autism. Treatment goals may be based on coherence anomalies identified by QEEG analysis. Based on specific patterns of increased or decreased coherence identified neurofeedback can be used to return these patterns to normal or near normal levels. Neurofeedback is typically based on an operant conditioning model, in which a computer analyzed signal is fed back to the trainee in real time along with a more easily understood signal on a computer monitor, which can be reinforced (Walker & Kozlowski, 2005). Increased coherence between brain regions may be downtrained, whereas decreased coherence between brain regions may be uptrained. Studies have shown that in addition to changing coherence as assessed by EEG, coherence training produces behavioral and functional improvements (Walker & Kozlowski, 2005; Walker et al., 2002). We propose and provide evidence that by identifying the specific coherence anomaly in Autism, neurofeedback can be used to remedy the aberrant connectivity pattern, resulting in cognitive and behavioral improvements as well. In sum, coherence anomalies may be the primary dysfunction in autism, EEG can

identify this, and neurofeedback can remedy it, at least in part.

The following images are shown as exemplars of the connectivity abnormalities that we have identified. These figures utilize the NRep analysis system (Hudspeth, 1999). The value, use, and interpretation of these images are discussed in detail in Hudspeth's (2008) article in the upcoming companion volume on connectivity. The interested reader can refer to this article as an aide to interpreting the images.

Frontotemporal Hyperconnectivity

Figures 1a and 1b show an autistic individual who displayed a pattern of bilateral frontotemporal interhemispheric hyperconnectivity. Evidence in support of this pattern comes from white matter functional anisotropy investigated through Diffusion Tensor Imaging (Barnea-Goraly et al., 2004), increases in cerebral white matter volume in frontal cortex (Herbert et al., 2004), abnormally small minicolumns in frontal areas (Buxhoeveden, Semendeferi, Schenker, & Courchesne, 2004), abnormally long and thin dendritic spines present in high density (Belmonte et al., 2004), and numerous studies showing behavioral and neuropsychological (executive) dysfunction (Courchesne & Pierce, 2005), all of which are suggestive of frontal dysfunction through overconnectivity. In an fMRI study, Mizuno et al. (2006) found more extensive connectivity in the left insula and right postcentral and middle frontal regions in comparison to control participants.

Coben and Padolsky (2007) performed the largest neurofeedback study demonstrating efficacy for Autism. Their individualized treatment protocol was based on the combined use of multiple assessment instruments (neuropsychological testing, rating scales, etc.) with a heavy emphasis on initial QEEG, which included analysis of absolute, relative power, and connectivity measures. Assessment-guided neurofeedback was conducted in 20 sessions with a focus on reducing hyperconnectivity, which was frequently observed in posterior frontal to

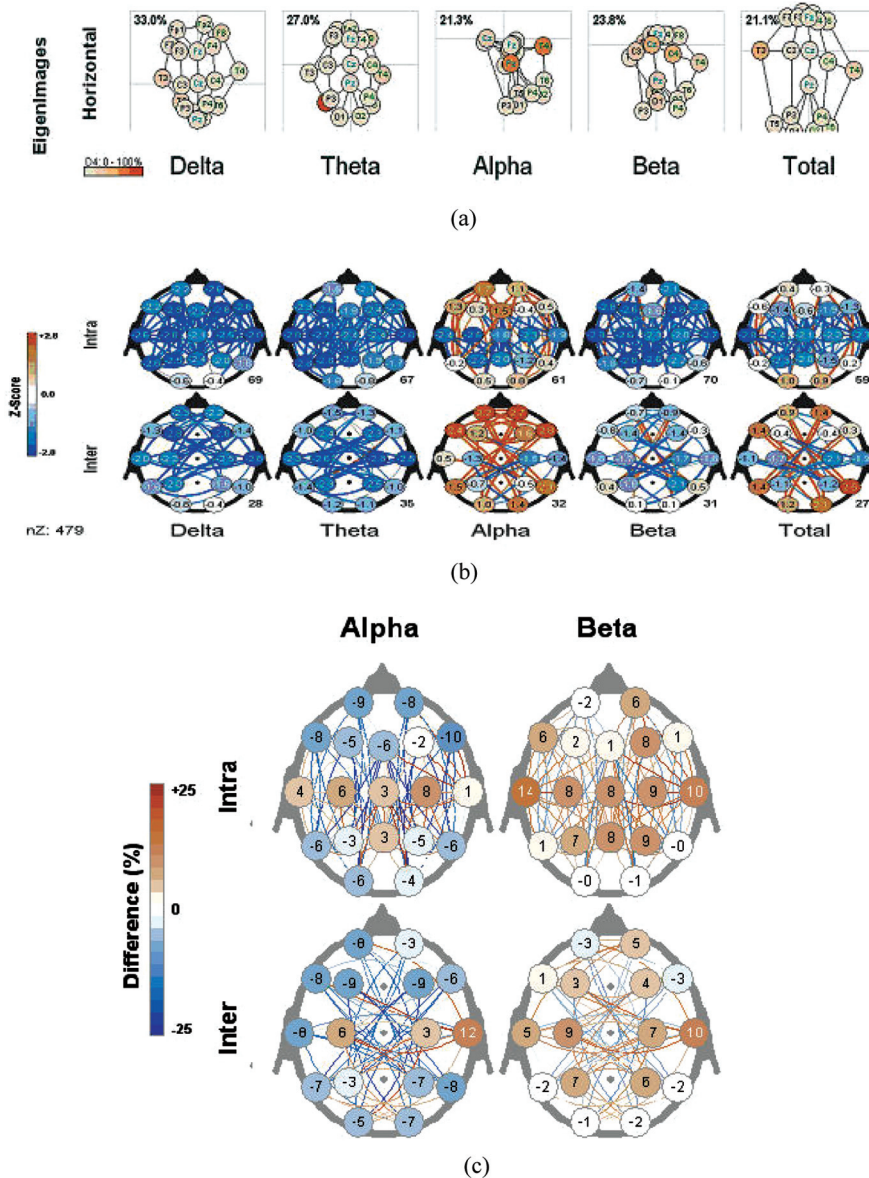
anterior-temporal regions. Their use of a bipolar montage permitted the neurofeedback to reinforce interhemispheric communication while reducing hyperconnectivity within and across brain regions. Reward bands were established based on the regions and frequencies of maximal hyperconnectivity. The hypothesis underlying this approach was that as the two waveforms at these locations become more disparate (i.e., reward band increases its amplitude), the coherence (or similarity) between the sites should decrease. QEEG analysis indicated that 77% of the experimental group showed a decrease in hyperconnectivity (see Figure 1c as an example of reduced connectivity following neurofeedback). The reduction of hyperconnectivity patterns in the experimental group was statistically significant; in addition, the reduction in cerebral hyperconnectivity was associated with positive clinical outcomes as indicated by reduced scores on the Autism Treatment Evaluation Checklist (Rimland & Edelson, 2000), Gilliam Asperger's Disorder Scale (Gilliam, 2001), Behavior Rating in Executive Functioning (Gioia, Isquith, Guy, & Kenworthy, 2000), and Personality Inventory for Children-2 (Lachar & Gruber, 2001). Improved ratings of ASD symptoms reflected an 89% success rate, and there was an average 40% reduction in core ASD symptomatology. The crucial factor in explaining improved clinical outcomes in the experimental group may be the use of assessment-guided neurofeedback to reduce cerebral hyperconnectivity.

Reducing interhemispheric bilateral hyperconnectivity in autistic children can lead to improvements in many realms. This often includes, but it is not limited to, enhancements of attention, self-regulatory functions, social behavior, and communication skills.

Frontal (Orbitofrontal) Hypoconnectivity

Figure 2a shows an example of an autistic individual with frontal (orbitofrontal) hypoconnectivity, an area implicated in many aspects of social behavior. Reasoning, the ability to represent the mental states of

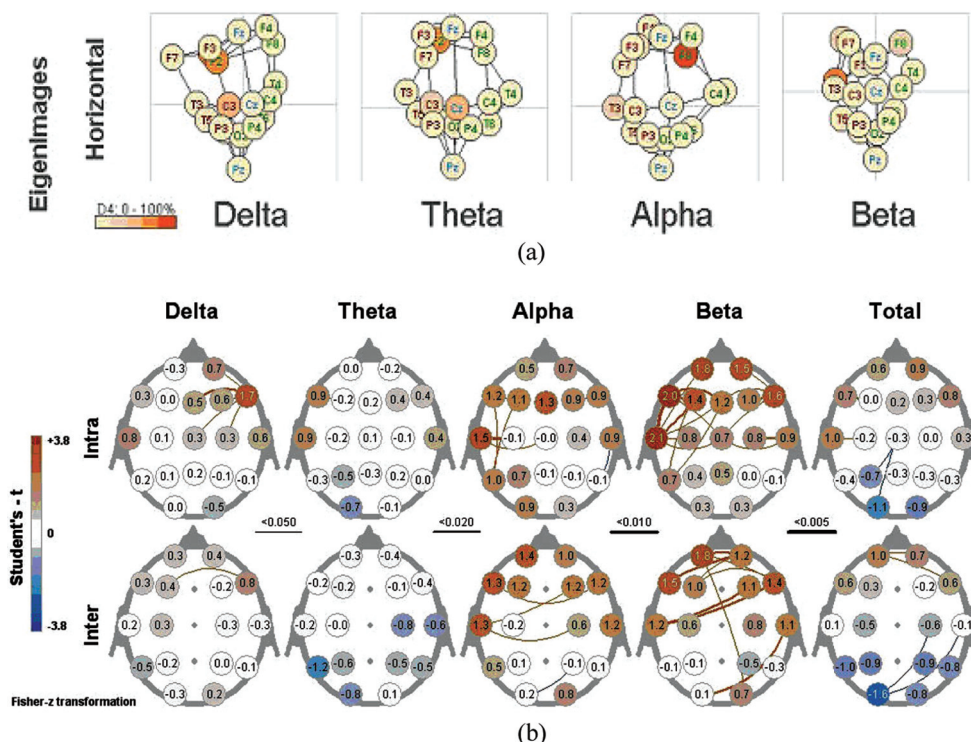
FIGURE 1. (a) Case example of an Autistic individual showing horizontal Eigenimages representing multivariate connectivity in Delta, Theta, Alpha, and Beta ranges, with frontal hyperconnectivity in the Alpha band. (b) Case example of an Autistic individual showing norm referenced multivariate connectivity z-score images with frontal hyperconnectivity in the Alpha band. Top row represents intrahemispheric coherence; bottom row represents interhemispheric connectivity. Greatest connectivity is shown interhemispherically. (c) Case example of an Autistic individual showing change scores in the measurement of multivariate connectivity, indicating a decrease in connectivity after treatment. Top row represents intrahemispheric connectivity; bottom row represents interhemispheric connectivity.



others, plays a crucial role in social abilities and has been established as a core deficit in Autism (Baron-Cohen, 2001). Neuropsychological evidence suggests that emotion recognition, thought to tap into theory of

mind abilities, may be impaired following amygdala and other orbitofrontal damage (Hornak, Rolls, & Wade, 1996). In a PET study, temporal hypoperfusion in the superior temporal gyrus and superior temporal

FIGURE 2. (a) Case example of an Autistic individual showing horizontal Eigenimages representing multivariate connectivity in Delta, Theta, Alpha, and Beta, with (orbitofrontal) hypoconnectivity in the Alpha band. Longer lines indicate less connectivity. (b) Averaged group data of Autistic individuals showing change scores in the measurement of multivariate connectivity, indicating an increase in connectivity after treatment with Passive Infrared Hemoencephalography (PIR HEG). Top row represents intrahemispheric connectivity; bottom row represents interhemispheric coherence. Greatest connectivity is shown intra- and interhemispherically.



sulcus was found in 77% of autistic children (Boddaert et al., 2002). Abnormalities have also been found in the functional integration of the amygdala and parahippocampal gyrus (Welchew et al., 2005). Sabbagh and Taylor (2000) performed an event-related potential study and identified orbitofrontal cortex and medial temporal cortex as strongly related to theory of mind decoding, based on the low-resolution electromagnetic tomography technique. Because this ability is known to be impaired in Autism, the authors conclude that this brain area is likely implicated in the disorder and may provide clues for effective therapeutic strategies.

Coben (2006) investigated the effects of hemoencephalography (HEG) neurofeedback on Autism symptoms. In this study, 28 autistic patients were provided assessment guided (based on neuropsychological testing,

EEG, and infrared [IR] imaging) near IR (NIR) or passive IR (PIR) HEG for at least 20 sessions, conducted twice weekly, for a duration of 15 to 25 min. A threshold-based control over a DVD player provided operant reinforcement of targeted brain activity. The objective was to increase the NIR/PIR HEG signal to exceed the threshold setting for the movie to continue or resume playing. Maximum output of IR radiation was associated with mental states of low anxiety and frustration while maintaining a high degree of sustained concentration. It is believed that prefrontal PIR HEG training tends to suppress dysregulated activity throughout the brain, not just frontally (Carmen, 2004). Results indicated significant and dramatic improvements in multiple areas, including social interaction, social communication, and cognitive impairments as rated by the Autism

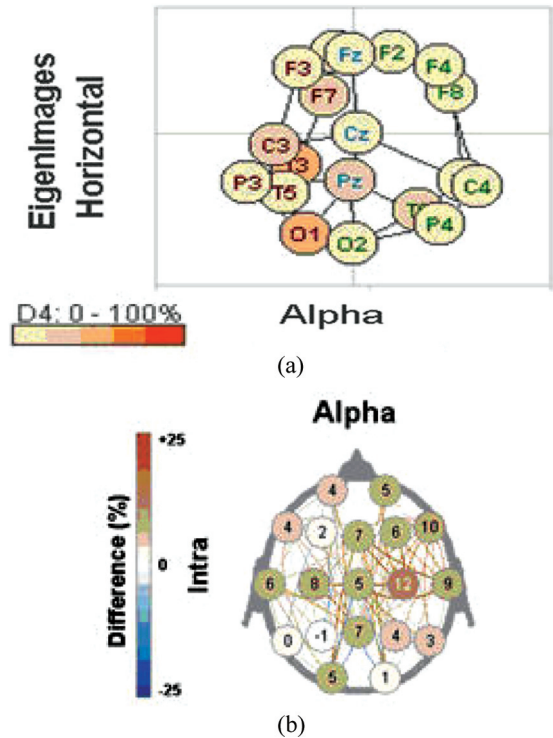
Treatment Evaluation Checklist. These functional improvements accompanied significant changes between pre- and post-EEG (see Figure 2b) and IR imaging sessions, which indicated an increase in frontal (orbitofrontal) connectivity. Coben's results indicate that remediating hypoconnectivity in orbitofrontal areas may result in social and behavioral improvements. This result is consistent with dysfunction in these areas in autism and neuropsychological studies implicating these brain areas with social behavior.

Mu Rhythm Complex

Mirror neurons were first discovered by Rizzolatti, Fadiga, Gallese, and Fogassi (1996) in the premotor cortex (area F5, or Broca's area in humans) of macaque monkeys with single unit electrode recordings. These are neurons that fire in response to the observation of an action by a conspecific (an organism belonging to the same species as another) that an individual would normally perform. This mirror neuron system (MNS) consists of an observation/execution system, which seems to be critical in the ability to understand and imitate other's behavior and has been implicated in several of the cognitive functions known to be impaired in Autism, including imitation, theory of mind, language, and empathy (Oberman et al., 2005). Oberman and colleagues recently found evidence of a dysfunctional MNS in high functioning individuals with ASD. EEG oscillations in the mu frequency (8–13Hz) over the sensorimotor cortex were associated with deficient mirror neuron activity. Mu power is reduced or suppressed in individuals with typical development when they perform movements or observe the actions of others. It was found that high-functioning individuals with ASD failed to suppress mu wave activity of the MNS while observing hand movement. In contrast, controls were able to suppress mu wave activity while observing as well as imitating hand movement.

Findings in Figure 3a show the mu rhythm complex (coherence patterns) as seen in an individual with autism. The presence of

FIGURE 3. (a) Case example of a horizontal image displaying mu rhythm complex in an individual with Autism. (b) Mu Rhythm Coherence Training showing an increase in connectivity and a corresponding decrease in Mu.



mu is a sign of dysfunction in the MNS, as it should be suppressed. In this figure, a large area of hypoconnectivity can be seen between central and frontal sites. The displacement of electrodes from where they normally would be causes some areas to be bunched up (hypercoherent) and others to be spread out (hypoconnective). Impairment in the MNS may contribute to social deficits in understanding and appropriately responding to other's behavior evident in high-functioning individuals with ASD (Oberman et al., 2005).

Because mu rhythm is generated by sensorimotor cortex and is suppressed when performing or observing an action, the disturbance of mu suppression in Autism is likely the result of a deficiency in coherence between central and frontal areas. This theory is also consistent with all the evidence suggesting deficient connectivity between

frontal and other areas, as described previously. If autistic individuals do not decrease mu while engaging in social activities, they likely will not learn how to interact effectively and in a way that facilitates healthy relationships. Coherence training, in which brain waves of specific frequency are trained to peak and trough at the same time, may allow for the suppression of mu. Coben, Hudspeth, Sherlin, Myers, and Kurowski (2008) examined connectivity and source localization of amplitude/power changes related to mu oscillations in autistic children. The findings showed mu to involve a system localized to temporo-limbic and frontal structures with hypoconnectivity between frontal and temporal/central sites. As a result, they theorized that increasing coherence between these regions might reduce mu oscillations. To test this hypothesis, Coben and Hudspeth (2006) provided EEG coherence training to autistic individuals by rewarding the coherence between central electrode sites with those of the lateral frontal region, where mirror neurons are located around the inferior frontal gyrus. Their results indicated significant reductions in mu activity (see Figure 3b for a sample of reduced mu activity) and improvements in social skills and social pragmatics. These reductions are shown as percentage increases in coherence. Areas with the largest change scores in area 3b correspond to area 3a which were shown to be hypo-coherent.

Right Posterior (Occipital-Parietal-Temporal) Hypoconnectivity

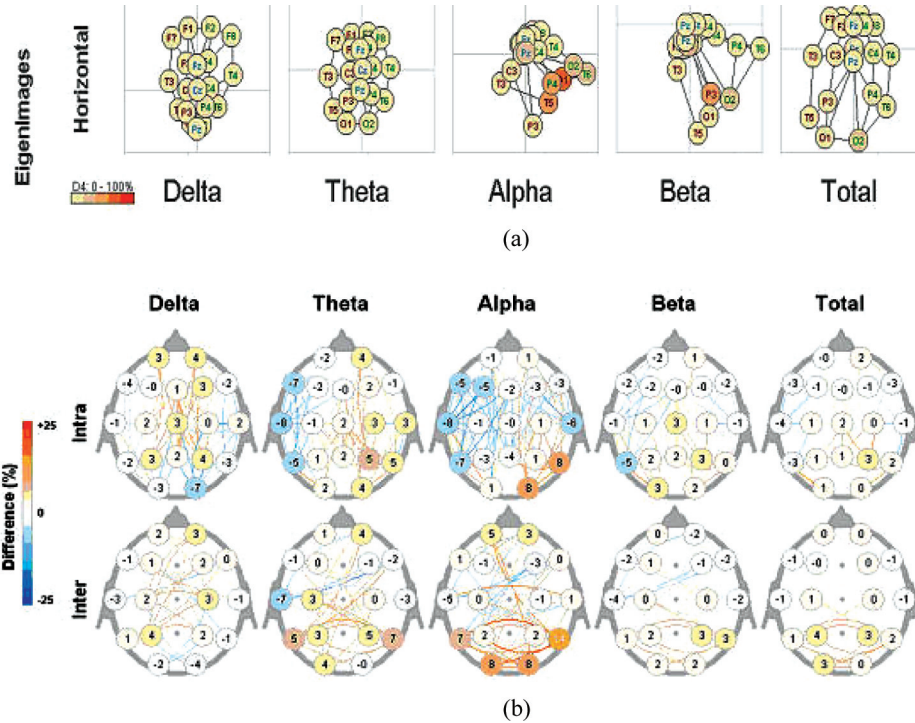
Coben et al. (2008) investigated quantitative EEG findings in Autism during an eyes-closed resting condition. Findings showed excessive slow wave (theta) activity over right posterior regions in addition to underconnectivity across delta, theta, and beta bands. Further evidence for posterior abnormal connectivity comes from studies of face processing. Behavioral studies have shown that autistic patients do not show the typically seen advantage of viewing faces upright as opposed to inverted (Hobson,

Ouston, & Lee, 1988) and that they tend to focus on facial features more than the gestalt of a face (Weeks & Hobson, 1987). Autistic patients do not appear to process faces in the same way as nonautistic individuals, suggesting there may be abnormal brain pathways involved. In fact, Pierce, Müller, Ambrose, Allen, and Courchesne (2001) demonstrated with fMRI that they do not use the same brain regions as a group of normal controls when viewing faces. Furthermore, whereas the control group showed maximum activation in the expected fusiform area, those in the autistic group showed a pattern of “individual-specific, scattered activation,” suggesting that faulty connections in this area preclude these individuals from using traditional areas used in face processing. Instead, of using traditional areas (fusiform), autistic individuals use idiosyncratic patterns of activation which allow them to process the information.

In addition, McPartland, Dawson, Webb, Panagiotides, and Carver (2004) conducted an event-related potential study to investigate the temporal dynamics of face processing in Autism. In their study the autistic group showed longer N170 latencies to faces but not to nonface objects and failed to show the expected longer N170 latency to inverted faces relative to upright faces. The fact that the autistic group processes inverted faces more similarly to upright faces than the control group can be taken to indicate that autistic individuals do not process faces the same as nonautistics. In this specific type of measurement (N170 latency), there was no difference between viewing faces upright or inverted for autistics.

One patient's EEG data showing right posterior hypoconnectivity is displayed in Figure 4a. Change scores in multivariate connectivity are depicted in Figure 4b, which indicate that following coherence training, connectivity increased in posterior regions. With increased connectivity in areas which were previously under connected, there will be increased communication and transfer of information. Coherence training between occipital-temporal and medial temporal

FIGURE 4. (a) Case example of an Autistic individual showing horizontal Neuroelectric Eigenimages representing multivariate connectivity in Delta, Theta, Alpha, Beta, and Total with right posterior hypoconnectivity. Longer lines indicate less connectivity. (b) Case example of an Autistic individual showing change scores in the measurement of multivariate connectivity, indicating an increase in right posterior connectivity after treatment. Top row represents intrahemispheric connectivity; bottom row represents interhemispheric connectivity.



areas on the right side increased coherence between these areas, which correspond to the areas of facial processing. Improvements following such coherence training often include enhanced social pragmatics, interaction skills, visual-perceptual/facial/prosodic processing skills. There are often associated improvements in attention and academic functioning as well.

Frontal–Posterior Hypoconnectivity

As previously noted, cortical underconnectivity between frontal and parietal areas was observed with fMRI during tasks of executive functioning (Just et al., 2007). Horowitz, Rumsey, Grady, and Rapoport (1988) used PET during a resting state to examine connectivity through glucose metabolism correlations in Autism and

found reduced intra- and interhemispheric connectivity between frontal and parietal areas. A recent functional connectivity magnetic resonance imaging study (fcMRI) investigated the integrity of the dorsal stream connection of visual information between occipital and posterior/superior parietal cortex (Villalobos, Mizuno, Dahl, Kemmotsu, and Müller, 2005). However, they also used this pathway to examine the involvement of frontal regions possibly containing mirror neurons, as evidence suggests that the dorsal stream also connects to frontal areas (Goodale, 2000). In an fMRI study of autistic men, Villalobos et al. (2005) found that, whereas functional connectivity between primary visual cortex and superior parietal regions was intact, connectivity between primary visual cortex and inferior frontal cortex (BA 44 and 45 areas presumed to contain mirror neurons) was significantly

reduced. The authors interpreted this finding as indicating a deficient connection between frontal areas containing mirror neurons and visual cortical areas, consistent with previous findings of mirror neuron dysfunction in Autism. Belmonte et al. (2004) reported preliminary EEG data on decreased and/or delayed gamma activity over the frontal cortex and visual processing areas, which they took to suggest disrupted neural signaling and abnormal regional activation patterns.

Recent EEG data collected on an autistic patient (see Figure 5a) serve as an example of Belmonte's findings and further support the frontal-posterior hypoconnectivity pattern seen in Autism. This pattern of hypoconnectivity can be reduced and coherence enhanced through coherence training. Figure 5b shows this increase in connectivity

between frontal and posterior regions, particularly in the Delta and Theta bands, following coherence training.

Left Hemisphere Hypoconnectivity

In a baseline-resting state fMRI study, Cherkassky et al. (2006) found that connectivity within the left hemisphere was significantly lower in an autistic group relative to a group of control subjects. As described previously, Just et al. (2004) measured functional connectivity with fMRI during a sentence comprehension task. They found that connectivity was lower throughout left hemisphere language areas relative to controls, indicating reduced synchronization and poor integration of information at more complex levels of processing, as

FIGURE 5. (a) Case example of an Autistic individual showing horizontal Neuroelectric Eigenimages representing multivariate connectivity in Delta, Theta, Alpha, Beta, and Total with frontal-posterior hypoconnectivity. Longer lines indicate less connectivity. (b) Case example of an Autistic individual showing change scores in the measurement of multivariate connectivity, indicating an increase in frontal-posterior connectivity after treatment. Top row represents intrahemispheric connectivity; bottom row represents interhemispheric connectivity.

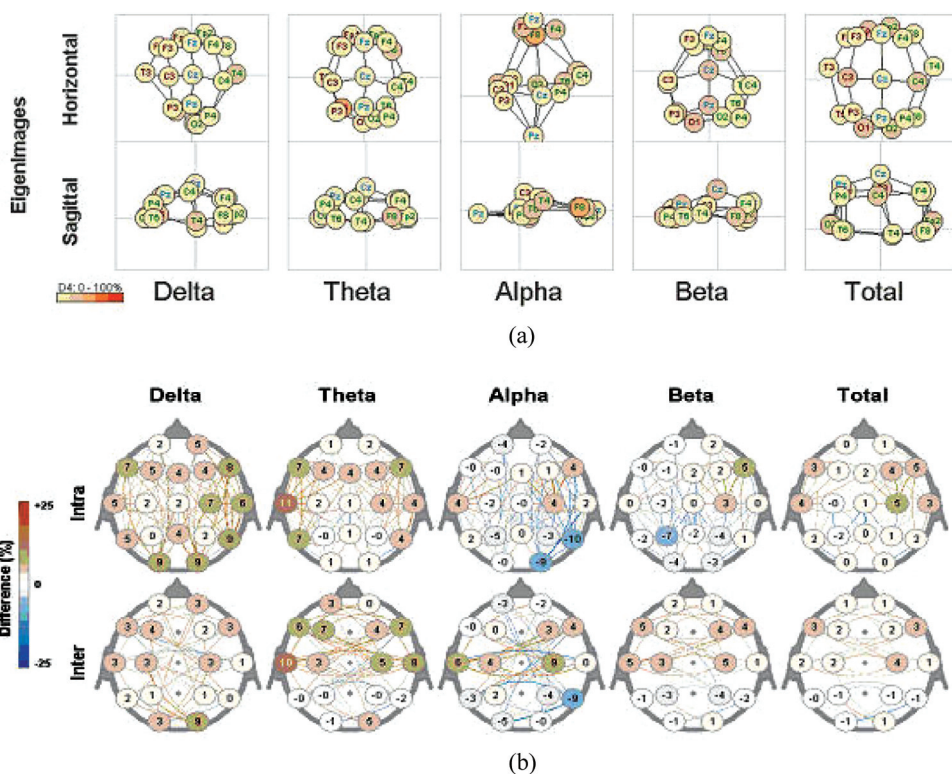
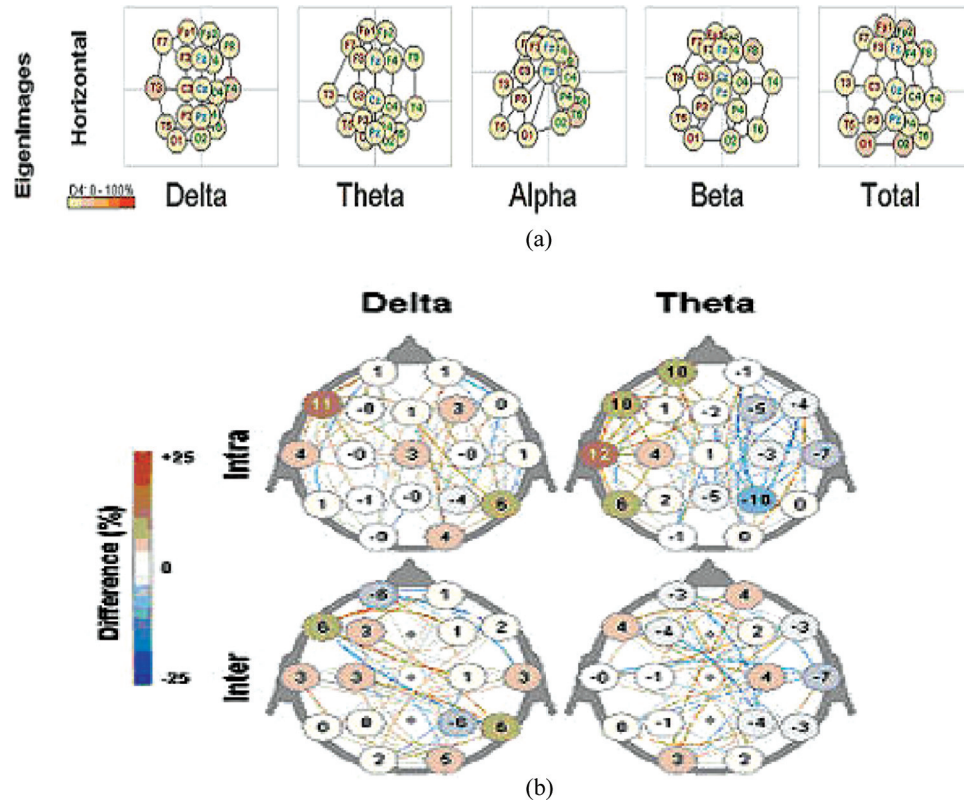


FIGURE 6. (a) Case example of an Autistic individual showing horizontal Neuroelectric Eigenimages representing multivariate connectivity in Delta, Theta, Alpha, Beta, and Total with left hemisphere hypoconnectivity. Longer lines indicate less connectivity. (b) Case example of an Autistic individual showing change scores in the measurement of multivariate connectivity, indicating an increase in left hemisphere coherence after treatment. Top row represents intrahemispheric connectivity; bottom row represents interhemispheric connectivity.



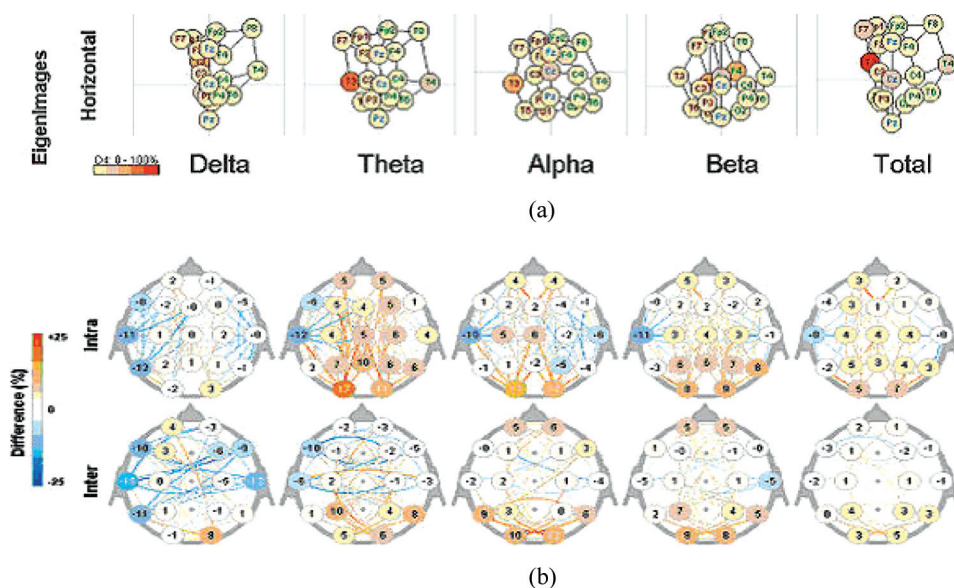
opposed to single word decoding which showed intact functioning. Figure 6a shows evidence of left hemisphere hypoconnectivity in an autistic individual. Decreased connectivity in the left hemisphere is indicated by the long lines between electrode sites of the left hemisphere. However, following coherence training, change scores in Figure 6b show a clear increase in connectivity in the Delta band, and particularly in the Theta band.

Left Hemisphere Intrahemispheric Hyperconnectivity

In contrast to the previous pattern of left hemisphere hypoconnectivity, Autism has

also been associated with a pattern of left hemisphere hyperconnectivity. Murias et al. (2007) examined EEG coherence during a resting state in male adults with Autism. They found increased coherence in the delta range of frontal and temporal regions of the left hemisphere in comparison to nonautistic individuals, suggesting local overconnectivity. Although there may be limited evidence from neuroimaging studies regarding hyperconnectivity in the left hemisphere in Autism, the language deficits apparent in almost all autistics suggests that the left hemisphere may be dysfunctionally connected. There is EEG evidence to suggest that autistics show atypical patterns of cerebral lateralization, in which the right hemisphere may be dominant for both

FIGURE 7. (a) Case example of an Autistic individual showing horizontal Neuroelectric Eigenimages representing multivariate connectivity in Delta, Theta, Alpha, Beta, and Total left hemisphere intrahemispheric hyperconnectivity. Longer lines indicate less connectivity. (b) Case example of an Autistic individual showing change scores in the measurement of multivariate connectivity, indicating a decrease in left hemisphere intrahemispheric connectivity after treatment. Top row represents intrahemispheric connectivity; bottom row represents interhemispheric connectivity.



language and spatial functions (Dawson, Warrenburg, & Fuller, 1982), further implicating abnormal left hemisphere functioning. As has been discussed throughout this article, Autism is associated with both under- and overconnectivity. Either pattern is abnormal so we would expect these individuals to express this dysfunction behaviorally. Figure 7a shows this pattern of left intrahemispheric hyperconnectivity in an autistic individual. Figure 7b shows a clear decrease in connectivity in the left hemisphere following coherence training.

Treatment of coherence anomalies over the left cerebral hemisphere often translates into improvements in communication and academic skills. As a result, improvements in other realms can be evident as well.

DISCUSSION

Autism has been associated with numerous neuroanatomical abnormalities, making

it difficult to pinpoint a specific cause of the behavioral manifestation of the disorder. The connectivity theory of Autism presents a new and empirically supported view of the cause of dysfunction seen. There are abnormalities in major white matter tracts that form the connections between neural regions (Chung et al., 2004, Herbert et al., 2004), particularly in the corpus callosum (Cherkassky et al., 2006; Courchesne et al., 1993; Just et al., 2007). Functional imaging demonstrated abnormal connectivity patterns (Cherkassky et al., 2006; Mizuno et al., 2006) and recent studies have used EEG coherence to show abnormal connectivity patterns (Coben et al., 2008; Coben & Hudspeth, 2006; Murias et al., 2007). We provide evidence for seven different aberrant connectivity patterns from existing research and clinical case examples and the value of EEG coherence in both the assessment and treatment of these patterns. These anomalous connectivity patterns form a beginning typology of the phenotypic expression of

underlying autistic brain dysfunction. Perhaps the most prominent pattern is that of frontal hyperconnectivity, in which frontal areas are overconnected with themselves, as proposed by Courchesne and Pierce (2005). This pattern leads to a lack of communication between frontal areas because existing connections are faulty. In addition, frontal areas are underconnected with other brain areas, rendering them unable to perform their normal integrative functions in directing other brain regions. Treatment goals may be based on coherence anomalies identified by QEEG analysis. By establishing reward bands between electrode sites, increased coherence between brain regions may be downtrained while decreased coherence between brain regions may be uptrained.

REFERENCES

- Alexander, A. L., Lee, J. E., Lazar, M., Boudos, R., DuBray, M. B., Oakes, T. R., et al. (2007). Diffusion tensor imaging of the corpus callosum in autism. *NeuroImage*, *34*, 61–73.
- American Psychiatric Association. (2000). *Diagnostic and statistical manual of mental disorders* (4th ed., text rev.). Washington, DC: Author.
- Attwood, T. (1998). *Asperger's syndrome: A guide for parents and professionals*. London: Jessica Kingsley.
- Bailey, A., Luthert, P., & Bolton, P. (1993). Autism and megalencephaly. *Lancet*, *341*, 1225–1226.
- Bailey, A., Luthert, P., Dean, A., Harding, B., Janota, I., Montgomery, M., et al. (1998). A clinicopathological study of autism. *Brain*, *121*, 889–905.
- Barnea-Goraly, N., Kwon, H., Menon, V., Eliez, S., Lotspeich, L., & Reiss, A. L. (2004). White matter structure in autism: Preliminary evidence from diffusion tensor imaging. *Biological Psychiatry*, *55*, 323–326.
- Baron-Cohen, S. (2001). Theory of mind and autism: A review. *International Review of Research in Mental Retardation*, *23*, 169–184.
- Belmonte, M. K., Allen, G., Beckel-Mitchener, A., Boulanger, L. M., Carper, R. A., & Webb, S. (2004). Autism and abnormal development of brain connectivity. *Journal of Neuroscience*, *24*(42), 9228–9231.
- Bertone, A., Mottron, L., Jelenic, P., & Faubert, J. (2005). Enhanced and diminished visuo-spatial information processing in autism depends on stimulus complexity. *Brain*, *128*(10), 2430–2441.
- Boddaert, N., Chabane, N., Barthelemy, C., Bourgeois, M., Poline, J. B., Brunelle, F., et al. (2002). Bitemporal lobe dysfunction in infantile autism: Positron emission tomography study. *Journal of Radiology*, *83*, 1829–1833.
- Boger-Megiddo, I., Shaw, D. W., Friedman, S. D., Sparks, B. F., Artru, A. A., Giedd, J. N., et al. (2006). Corpus callosum morphometrics in young children with autism spectrum disorder. *Journal of Autism and Developmental Disorders*, *36*(6), 733–739.
- Buxhoeveden, D., Semendeferi, K., Schenker, N., & Courchesne, E. (2004). Decreased cell column spacing in autism. *Society for Neuroscience Abstracts*, *30*.
- Cantor, D. S., Thatcher, R. W., Hrybyk, M., & Kaye, H. (1986). Computerized EEG analyses of autistic children. *Journal of Autism and Developmental Disorders*, *16*(2), 169–187.
- Carmen, J. A. (2004). Passive infrared hemoencephalography: Four years and 100 migraines. *Journal of Neurotherapy*, *8*(3), 23–51.
- Casanova, M. F., Buxhoeveden, D. P., & Brown, C. (2002). Clinical and macroscopic correlates of minicolumnar pathology in autism. *Journal of Child Neurology*, *17*(9), 692–695.
- Centers for Disease Control and Prevention. (2006). *How common are autistic spectrum disorders (ASD)?* Atlanta, GA: Author. Retrieved December 1, 2006, from http://www.cdc.gov/ncbddd/autism/asd_common.htm
- Cherkassky, V. L., Kana, R. K., Keller, T. A., & Just, M. A. (2006). Functional connectivity in a baseline resting-state network in autism. *NeuroReport*, *17*(16), 1687–1690.
- Chung, M. K., Dalton, K. M., Alexander, A. L., & Davidson, R. J. (2004). Less white matter concentration in Autism: 2D voxel-based morphometry. *NeuroImage*, *23*(1), 242–251.
- Coben, R. (2006, September). *Hemoencephalography for Autistic Spectrum Disorder*. Paper presented at the 14th Annual Conference of the International Society for Neuronal Regulation, Atlanta, GA.
- Coben, R., Clarke, A. R., Hudspeth, W., & Barry, R. J. (2008). EEG power and coherence in Autistic Spectrum Disorder. *Clinical Neurophysiology*, *119*, 1002–1009.
- Coben, R., & Hudspeth, W. (2006, September). *Mu-like rhythms in autistic spectrum disorder: EEG analyses and neurofeedback outcome*. Paper presented at the 14th Annual Conference for the International Society for Neuronal Regulation, Atlanta, GA.
- Coben, R., Hudspeth, W. J., Sherlin, L., Myers, T., & Kurowski, D. (2008). *Mu oscillations in autistic children: Source localization and connectivity analyses*. Manuscript in preparation.

- Coben, R. & Padolsky, I. (2007). Assessment-guided neurofeedback for autistic spectrum disorder. *Journal of Neurotherapy*, 11(1), 5–23.
- Courchesne, E. (2004). Brain development in autism: Early overgrowth followed by premature arrest of growth. *Mental Retardation and Developmental Disabilities Research Reviews*, 10, 106–111.
- Courchesne, E., Carper, R., & Akshoomoff, N. (2003). Evidence of brain overgrowth in the first year of life in autism. *Journal of the American Medical Association*, 290, 337–344.
- Courchesne, E., Karns, C. M., Davis, H. R., Ziccardi, R., Carper, R. A., Tigue, Z. D., et al. (2001). Unusual brain growth patterns in early life in patients with autistic disorder: An MRI study. *Neurology*, 57, 245–254.
- Courchesne, E., Muller, R. A., & Saitoh, O. (1999). Brain weight in autism: Normal in the majority of cases, megalencephalic in rare cases. *Neurology*, 52, 1057–1059.
- Courchesne, E. & Pierce, K. (2005). Why the frontal cortex in autism might be talking only to itself: Local over-connectivity but long-distance disconnection. *Current Opinion in Neurobiology*, 15, 225–230.
- Courchesne, E., Press, G. A., & Yeung-Courchesne, R. (1993). Parietal lobe abnormalities detected with MR in patients with infantile autism. *American Journal of Roentgenology*, 160, 387–393.
- Courchesne, E., Redcay, E., Morgan, J. T., & Kennedy, D. P. (2005). Autism at the beginning: Microstructural and growth abnormalities underlying the cognitive and behavioral phenotype of autism. *Development and Psychopathology*, 17, 577–597.
- Davidovitch, M., Patterson, B., & Gartside, P. (1996). Head circumference measurements in children with autism. *Journal of Child Neurology*, 11, 389–393.
- Dawson, G., Warrenburg, S., & Fuller, P. (1982). Cerebral lateralization in individuals diagnosed as Autistic in early childhood. *Brain and Language*, 15, 353–368.
- Filipek, P. A., Richelme, C., Kennedy, D. N., Rademacher, J., Pitcher, D. A., Zidel, S., et al. (1992). Morphometric analysis of the brain in developmental language disorders and autism. *Annals of Neurology*, 32, 475.
- Frith, C. (2003). What do imaging studies tell us about the neural basis of autism?. *Novartis Foundation Symposium*, 251, 149–166.
- Gilliam, J. E. (2001). *Gilliam asperger's disorder scale examiner's manual*. Austin, Texas: Pro-Ed.
- Gioia, G. A., Isquith, P. K., Guy, S. C., & Kenworthy, L. (2000). *Behavior rating inventory of executive function*. Lutz, FL: Psychological Assessment Resources.
- Goodale, M. A. (2000). Occipitotemporal and occipitoparietal visual pathways in the primate brain. *Advances in Neurology*, 84, 75–86.
- Hamilton, L. (2000) *Facing autism: Giving parents reasons for hope and guidance for help*. Colorado Springs, CO: WaterBrook Press.
- Herbert, M. R. (2005). Large brains in Autism: The challenge of pervasive abnormality. *The Neuroscientist*, 11(5), 417–440.
- Herbert, M. R., Ziegler, D. A., Deutsch, C. K., O'Brien, L. M., Lange, N., Bakardjiev, A., et al. (2003). Dissociations of cerebral cortex, subcortical and cerebral white matter volumes in autistic boys. *Brain*, 126, 1182–1192.
- Herbert, M. R., Ziegler, D. A., Makris, N., Filipek, P. A., Kemper, T. L., Normandin, J. J., et al. (2004). Localization of white matter volume increase in autism and developmental language disorder. *Annals of Neurology*, 55(4), 530–540.
- Hobson, R. P., Ouston, J., & Lee, A. (1988). What's in a face? The case of autism. *British Journal of Psychology*, 79, 441–453.
- Hornak, J., Rolls, E. T., & Wade, D. (1996). Face and voice expression identification in patients with emotional and behavioural changes following ventral frontal lobe damage. *Neuropsychologia*, 34, 247–261.
- Horowitz, B., Rumsey, J., Grady, C., & Rapoport, S. (1988). The cerebral metabolic landscape in autism. *Archives of Neurology*, 45, 749–755.
- Hudspeth, W. J. (1999). *NeuroRep: The QEEG analysis and report system*. Los Osos, CA: Neuropsychometrix.
- Hudspeth, W. J. (2008). Multivariate connectivities within a spherical brain space. *Journal of Neurotherapy* (forthcoming).
- Hughes, J. R. (2007). Autism: The first firm finding = underconnectivity? *Epilepsy and Behavior*, 11(1), 20–24.
- Just, M. A., Cherkassky, V. L., Keller, T. A., Kana, R. K., & Minshew, N. J. (2007). Functional and anatomical cortical underconnectivity in autism: Evidence from an fMRI study of an executive function task and corpus callosum morphometry. *Cerebral Cortex*, 17(4), 951–961.
- Just, M. A., Cherkassky, V. L., Keller, T. A., & Minshew, N. J. (2004). Cortical activation and synchronization during sentence comprehension in high-functioning autism: Evidence of underconnectivity. *Brain*, 127(8), 1811–1821.
- Kanner, L. (1943). Autistic disturbances of affective contact. *Nervous Child*, 2, 217–307.
- Kemper, T. L. & Bauman, M. L. (1993). The contribution of neuropathologic studies to the understanding of autism. *Behavioral Neurology*, 11, 175–187.

- Kemper, T. L. & Bauman, M. (1998). Neuropathology of infantile autism. *Journal of Neuropathology and Experimental Neurology*, 57, 645–652.
- Lachar, D. & Gruber, C. P. (2001). *Personality inventory for children, second edition*. Los Angeles, CA: Western Psychological Services.
- McAlonan, G. M., Cheung, V., Cheung, C., Suckling, J., Lam, G. Y., Tai, K. S., et al. (2005). Mapping the brain in autism: A voxel-based MRI study of volumetric differences and intercorrelations in autism. *Brain*, 128(2), 268–276.
- McCandless, J. (2005). *Children with starving brains: A medical treatment guide for autism spectrum disorder*. Putney, VT: Bramble Books.
- McPartland, J., Dawson, G., Webb, S. J., Panagiotides, H., & Carver, L. J. (2004). Event-related brain potentials reveal anomalies in temporal processing of faces in autism spectrum disorder. *Journal of Child Psychology and Psychiatry*, 45(7), 1235–1245.
- Mizuno, A., Villalobos, M. E., Davies, M. M., Dahl, B. C., & Muller, R. A. (2006). Partially enhanced thalamocortical functional connectivity in autism. *Brain Research*, 1104(1), 160–174.
- Murias, M., Webb, S. J., Greenson, J., & Dawson, G. (2007). Resting state cortical connectivity reflected in EEG Coherence in individuals with Autism. *Biological Psychiatry*, 62(3), 270–273.
- Murphy, D. G. M., Critchley, H. D., Schmitz, N., McAlonan, G., Van Amelsvoort, T., Robertson, D., et al. (2002). A Proton magnetic resonance spectroscopy study of the brain. *Archives of General Psychiatry*, 59(10), 885–891.
- Nunez, P. L. (1995). *Neocortical dynamics and human EEG rhythms*. New York: Oxford University Press.
- Nunez, P. L. & Srinivasan, R. (2006). *Electric fields of the brain: The neurophysics of EEG* (2nd ed.). New York: Oxford University Press.
- Oberman, L. M., Hubbard, E. M., McCleery, J. P., Altschuler, E. L., Ramachandran, V. S., & Pineda, J. A. (2005). EEG evidence for mirror neuron dysfunction in autism spectrum disorders. *Cognitive Brain Research*, 24, 190–198.
- Otnes, R. K. & Enochson, L. (1972). *Digital time series analysis*. New York: Wiley & Sons.
- Page, L. A., Daly, E., Schmitz, N., Simmons, A., Toal, F., Deeley, Q., et al. (2006). In vivo H-magnetic resonance spectroscopy study of amygdala-hippocampal and parietal regions in autism. *American Journal of Psychiatry*, 163, 2189–2192.
- Pelphrey, K. A., Adolphs, R., & Morris, J. P. (2005). Neuroanatomical substrates of social cognition dysfunction in autism. *Mental Retardation and Developmental Disabilities Research Reviews*, 10, 259–271.
- Pierce, K., Müller, R.-A., Ambrose, J., Allen, G., & Courchesne, E. (2001). Face processing occurs outside the fusiform “face area” in autism: Evidence from fMRI. *Brain*, 124, 2059–2073.
- Piven, J., Arndt, S., Bailey, J., & Andreasen, N. (1996). Regional brain enlargement in autism: A magnetic resonance imaging study. *Journal of the American Academy of Child and Adolescent Psychiatry*, 35, 530–536.
- Piven, J., Bailey, J., Ranson, B. J., & Arndt, S. (1997). An MRI study of the corpus callosum in autism. *American Journal of Psychiatry*, 154, 1051–1056.
- Rimland, B. & Edelson, S. M. (2000). *Autism treatment evaluation checklist (ATEC)*. Retrieved October 23, 2007, from <http://www.autismeval.com/ari-atec/report1.html>
- Rizzolatti, G., Fadiga, L., Gallese, V., & Fogassi, L. (1996). Premotor cortex and the recognition of motor actions. *Cognitive Brain Research*, 3, 131–141.
- Rorke, L. B. (1994). A perspective: the role of disordered genetic control of neurogenesis in the pathogenesis of migration disorders. *Journal of Neuropathology and Experimental Neurology*, 53, 105–117.
- Sabbagh, M. A. & Taylor, M. (2000). Neural correlates of theory of mind reasoning in adults: An event-related potential study. *Psychological Science*, 11, 46–50.
- Schmitz, N., Rubia, K., Daly, E., Smith, A., Williams, S., & Murphy, D. G. (2006). Neural correlates of executive function in autistic spectrum disorders. *Biological Psychiatry*, 59(1), 7–16.
- Sicile-Kira, C. (2004). *Autism spectrum disorders: The complete guide to understanding autism, asperger's syndrome, pervasive developmental disorder, and ASDs*. New York: Berkley.
- Siegel, B. (1996). *The world of the autistic child: Understanding and treating autistic spectrum disorders*. New York: Oxford University Press.
- Tidmarsh, L. & Volkmar, F. R. (2003). Diagnosis and epidemiology of autism spectrum disorders. *Canadian Journal of Psychiatry*, 48(8), 517–525.
- Vidal, C. N., Nicolson, R., DeVito, T. J., Hayashi, K. M., Geaga, J. A., Drost, D. J., et al. (2006). Mapping corpus callosum deficits in autism: An index of aberrant cortical connectivity. *Biological Psychiatry*, 60(3), 218–225.
- Villalobos, M. E., Mizuno, A., Dahl, B. C., Kemmotsu, N., & Müller, R.-A. (2005). Reduced functional connectivity between V1 and inferior frontal cortex associated with visuo-motor performance in autism. *NeuroImage*, 25, 916–925.

- Walker, J. E. & Kozlowski, G. P. (2005). Neurofeedback treatment of epilepsy. *Child and Adolescent Psychiatric Clinics of North America*, 14, 163–176.
- Walker, J. E., Norman, C. A., & Weber, R. K. (2002). Impact of qEEG-guided coherence training for patients with a mild closed head injury. *Journal of Neurotherapy*, 6(2), 31–43.
- Weeks, S. J. & Hobson, R. P. (1987). The salience of facial expression for autistic children. *Journal of Child Psychology and Psychiatry and Allied Disciplines*, 28, 137–151.
- Welchew, D. E., Ashwin, C., Berkouk, K., Salvador, R., Suckling, J., Baron-Cohen, S., et al. (2005). Functional disconnectivity of the medial temporal lobe in asperger's syndrome. *Biological Psychiatry*, 57, 991–998.
- Wickelgren, I. (2005). Autistic brains out of synch?. *Science*, 308, 1856–1858.